

Such cases often cause confusion in Medical Retina clinics as to the precise nature. This summary from Dr Browning is really helpful I enclose my case at the end.

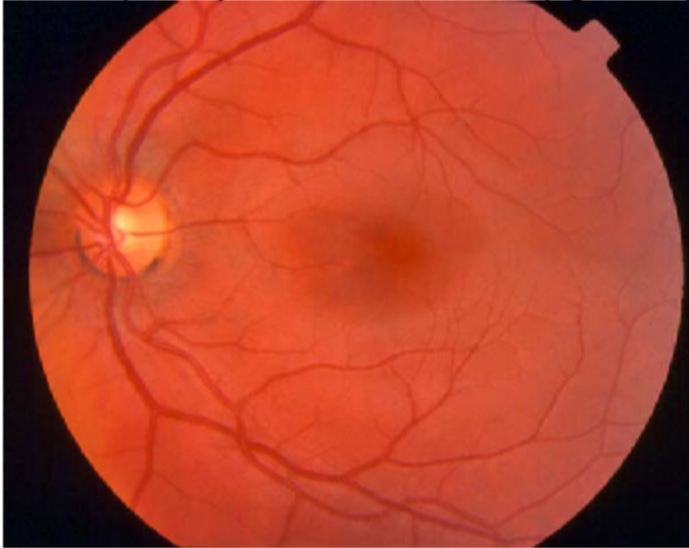What You Should Know About Macular Pattern Dystrophy

By David J. Browning MD, PhD

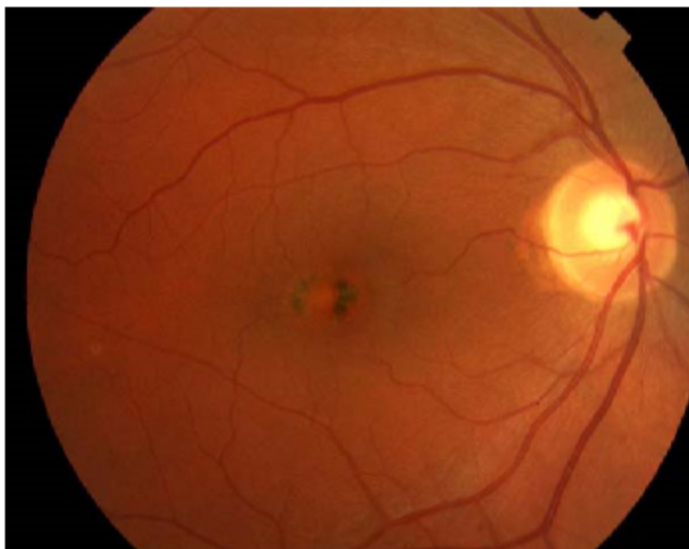
Macular pattern dystrophy is a disease of the retina which is commonly confused with macular degeneration, but is actually milder in its effect on the patient. The purpose of this brochure is to clear up some of the differences between macular degeneration, which is extremely common, and macular pattern dystrophy, which is much rarer.

The retina, which lines the back of the eye like the film in a camera, has many layers. The deepest layer is called the retinal pigment epithelium. This is the layer affected by pattern

dystrophy. The retinal pigment epithelium is devoted to processing waste material made by the rest of the retina. In pattern dystrophy, the waste is not properly eliminated. Instead, it builds up within the cells as a material called lipofuscin. The distended cells of the retinal pigment epithelium form visible patterns to the doctor looking into the eye, hence the name pattern macular dystrophy. The more commonly seen patterns include butterfly-shaped, egg-yolk shaped (vitelliform), and net shaped (reticular and macroreticular dystrophies).



Normal Retina



Retina with Macular Pattern Dystrophy

What Causes Macular Pattern Dystrophy?

Macular pattern dystrophy is a "wastebasket" name for many mutations affecting several genes. Each year new genetic mutations are discovered which lead to abnormal proteins in the cells of the retinal pigment epithelium, which in turn produce the visible pigment figures in the patient's retinas. The most common mutations causing macular pattern dystrophy involve chromosome 11 in a gene called retinal dystrophy slow. This gene, or string of DNA, codes for a protein important in photoreceptors. When the gene is mutated, the resulting protein is abnormally shaped and cannot properly perform its functions in the cell. These mutations can be inherited by children of affected patients, usually in an autosomal dominant fashion. This means that a child of a patient with this disease has a 50% chance of inheriting the mutated gene. The resulting pigment figures in successive generations may not look the same, evidence that other factors are important in causing the exact appearance of a particular macular pattern dystrophy. It is possible that environmental factors, such as diet, play a modulating role, or that other genes can affect the expression of the mutation causing pattern dystrophy.

Is There Any Cure or Treatment For Macular Pattern Dystrophy?

At present there is no treatment for macular pattern dystrophy. Because the number of patients having the disease is small, the research attention given to finding the cause of the disease and finding a cure is modest. The main goal of periodically examining patients with the condition is to maximize sight with proper glasses, and to ensure that other, more treatable diseases are not overlooked. Perhaps 15% of patients with macular pattern dystrophy will develop growth of a blood vessel under the retina, usually after age 60, which can cause relatively rapid loss of reading vision¹. For this reason, patients with macular pattern dystrophy are advised to look at a piece of graph paper called an Amsler grid on a regular basis. If the lines begin to look distorted or blurred in an area of the grid, the patient should be seen soon – within a day or two. Eyes with these problem may need laser treatment or an injection of a drug blocking blood vessel growth. Perhaps 20% of patients will develop areas of retinal photoreceptor and pigment epithelial cell loss, again usually after age 60, with loss of reading vision but not peripheral vision¹. This problem is called geographic atrophy, and as yet has no treatment.

What Is the Prognosis for Vision in Macular Pattern Dystrophy?

The prognosis is much better in macular pattern dystrophy than in macular degeneration. Usually patients retain the ability to read a newspaper and drive into old age. The patient may lose some visual acuity and have complaints of blurred vision, but the severity is milder than in macular degeneration. In some cases, a visit to the Low Vision Clinic may be worthwhile to help with specific tasks such as looking up phone numbers or threading needles.

After reading this brochure, if you have questions, please call me at 704-295-3180 to discuss them. If you are interested in delving into the topic in greater detail, an excellent website is <http://www.ncbi.nlm.nih.gov/PubMed/>.

Reference List

1. Francis PJ, Schultz DW, Gregory AM, et al. Genetic and phenotypic heterogeneity in pattern dystrophy. Br J ophthalmol 89, 1115-1119. 2005.

Updated 10/7/2005

This man aged 62 had noticed reduced vision to 6/12 for 8 years. His optician referred him for wet amd treatment. He has a dry OCT scan, but these stellate type pattern of pale lines and pigmentation. He has a type of Macular Dystrophy as nicely explained above. We discharged him from the clinic and advised annual photographs from his optometrist

