

[2011 anti-VEGF Treatments for Diabetic Macular Oedema.](#)



The Hillingdon Hospital / The Western Eye Hospital has been a Macular centre since 2000 and been using Anti-VEGF for DIABETIC MACULAR OEDEMA for the past 4 years. We thus have considerable experience of this treatment. Our audited results are in line with national results.

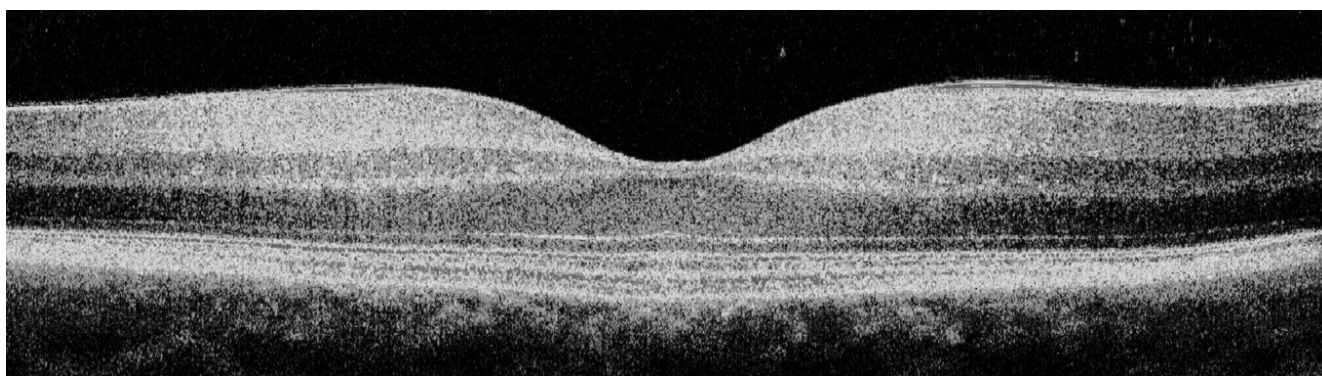
Anti-VEGF treatments have been initially developed very successfully for wet Age related macular degeneration. However it became very evident that these drugs were also very useful in a wide range of other eye conditions where there was leakage of fluid into the retina.

History of the Development of Treatments

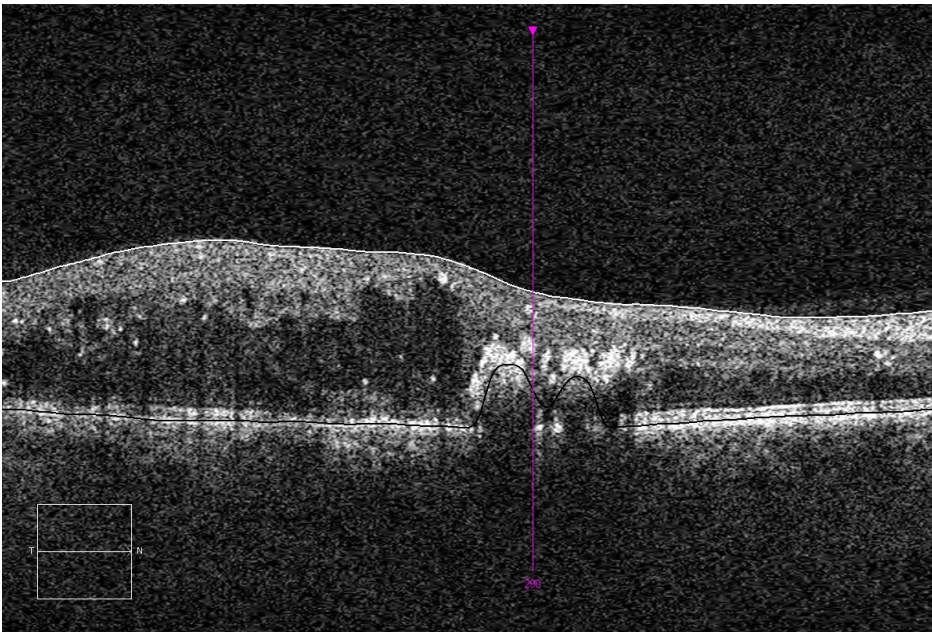
1. 1976's Several landmark studies confirmed that Argon Laser was tremendously beneficial in treating diabetic retinopathy. This has been the main stay of treatment. It is especially helpful in diabetic macular oedema that is not central, and for proliferative eye disease. However if there is fluid at the fovea or in the very centre of the vision, laser is less effective as you cannot laser the centre of the vision! Hence the search for a pharmaceutical agent that will treat the fluid at the centre of the vision.
2. 2000 Intravitreal steroids used for diabetic macular oedema. Side effects of raised eye pressure and cataracts and transient responses put this being widely accepted.
3. 2006 Macugen licensed First Anti-VEGF treatment for Age related macular degeneration, but never gained NICE approval and little used. Possibility of Licence for diabetic macular oedema in 2011.
4. 2006 Avastin Off-label use of this Cancer drug which is very similar to Lucentis. No Drug company research, but many small clinical studies done by doctors. Both USA and UK government have organised Publically funded research trials to determine if it is as effective and as safe as Lucentis. The US CATT trial shows slight superiority for Lucentis in Age related macular degeneration.
5. 2007 Lucentis licensed in Europe for wet Age related macular degeneration .
6. 2011 Lucentis licensed for diabetic macular oedema and Vein Occlusions in the UK.

7. NICE declined NHS Funding for Lucentis in diabetic macular oedema due to the costs involved in treating both eyes, they acknowledged its effectiveness though.
8. 2012 onwards. Many new drugs (VEGF Traps etc..) are being very actively developed by manufactures as well as more user friendly delivery systems for these drugs.

Trials of Avastin (Bevacizumab) in cystoid macular oedema in diabetes are being undertaken for both Avastin (Bevacizumab) and Lucentis and are showing very promising results with improvements of one to 3 lines of vision over a year.



Above is a normal Optical Coherence scan of the eye, below is a diabetic with diffuse Macular oedema. One can see the damage to the retina below. Laser is relatively ineffective as you cannot treat the centre of the vision. Anti-VEGF and steroids injected into the eye get right on to the affected retina and dry the fluid, and subsequently improving/stabilising the vision. Treatment is aimed at resolving the fluid.



However others experience and our experience is that Avastin (Bevacizumab) intravitreal injections works slowly and that it is quite likely that monthly to 6 weekly injections will be required for a year or more. The long term benefits are unknown. It is not known what happens when you stop treating, does the cystoid macular oedema return or does the retina stay dry.

A quote from a recent paper in the Medical Journal "EYE" in 2009 concluded " Avastin (Bevacizumab) application provides significant improvement in vision of diabetic patients and the clinical course of macular oedema, an may therefore be a promising approach in the primary treatment of diabetic macular oedema"

Primary Intravitreal Bevacizumab for Diffuse Diabetic Macular Edema

*The Pan-American Collaborative Retina Study Group
at 24 Months*

Results:

The mean age of the patients was 59.4_11.1 years.

The mean number of IVB injections per eye was 5.8 (range, 1–15 injections).

In the 1.25-mg group at 1 month, BCVA improved from 20/150 (0.88 logarithm of the minimum angle of resolution [logMAR] units) to 20/107, 0.76 logMAR units (P_0.0001).

The mean BCVA at 24 months was 20/75 (0.57 logMAR units; P_0.0001).

Similar BCVA changes were observed in the 2.5-mg group: at 1 month, BCVA improved from 20/168 (0.92 logMAR units) to 20/118 (0.78 logMAR units; P = 0.02).

The mean BCVA at 24 months was 20/114 (0.76 logMAR units; P = 0.0001).

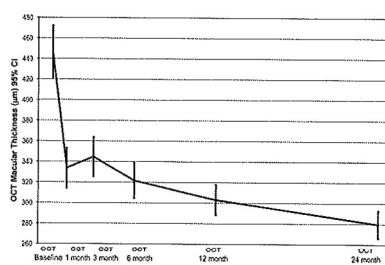
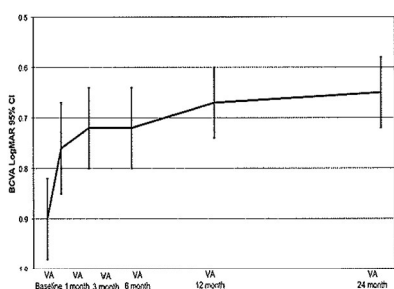
In the 1.25-mg group, the mean central macular thickness (CMT) decreased from 466.5 ± 145.2 µm at baseline to 332.2 ± 129.6 µm at 1 month and 286.6 ± 81.5 µm at 24 months (P = 0.0001).

Similar results were obtained in the 2.5-mg group.

Conclusions: Primary IVB at doses of 1.25 to 2.5 mg seem to provide stability or improvement in BCVA, OCT, and FA in DDME at 24 months.

I feel that there is sufficient published papers on the subject of diabetic macular oedema to offer this to Patients while further research is undertaken.

Results

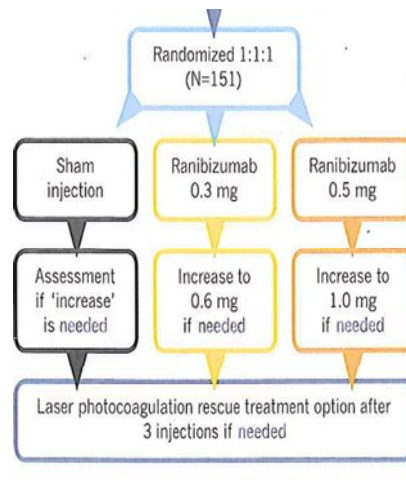


Resolve trial – Lucentis in diabetic macular oedema.

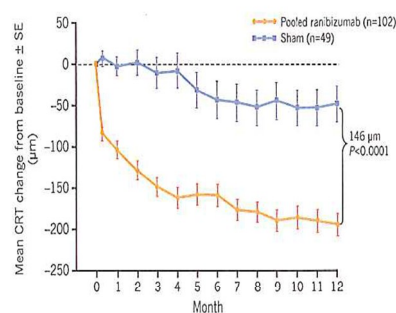
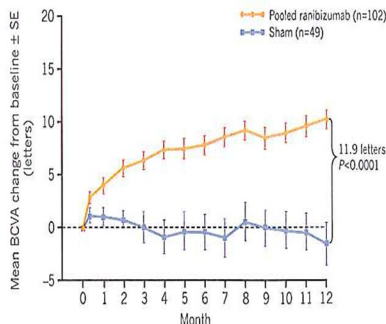
This Randomised controlled trial of Lucentis has clearly shown the benefits of Lucentis for diabetic macular oedema. It also showed that additional laser either before or after treatment did not improve the outcome. In fact Lucentis alone proved to be the most effective treatment and considerably superior to laser alone.

Resolve Trial

- 1 Yr RCT Phase II, Europe, Australia, Asia
- >18 years old
- Type 1 or 2
- Focal or diffuse diabetic macular oedema
- Has to have Foveal oedema.



Summary results.



2011 Lucentis has been assessed by NICE whose initial ruling is that as many patients require (35%) bilateral treatment the benefits of treating the second eye are scored less well on Quality of Life assessments and consequently the treatment becomes far more expensive and goes beyond NICE limit for cost effectiveness. This is currently being appealed though.

It must however be pointed out that Lucentis or Avastin (Bevacizumab) treatment is considerable work and demands considerable commitment from patients. It involves either monthly injections or monthly reviews. It is not a quick fix and typically

patients will need 6 or more injections in the first year and slightly less in the second year. It is not a quick fix, it is slow progress that takes times and numerous injections.

In contrast Laser is a quick single treatment that works over 4 months and continues to work over 18 months. Laser can be repeated if needed ever 4 months if needed. Thus far fewer visits to the clinic are needed for laser.

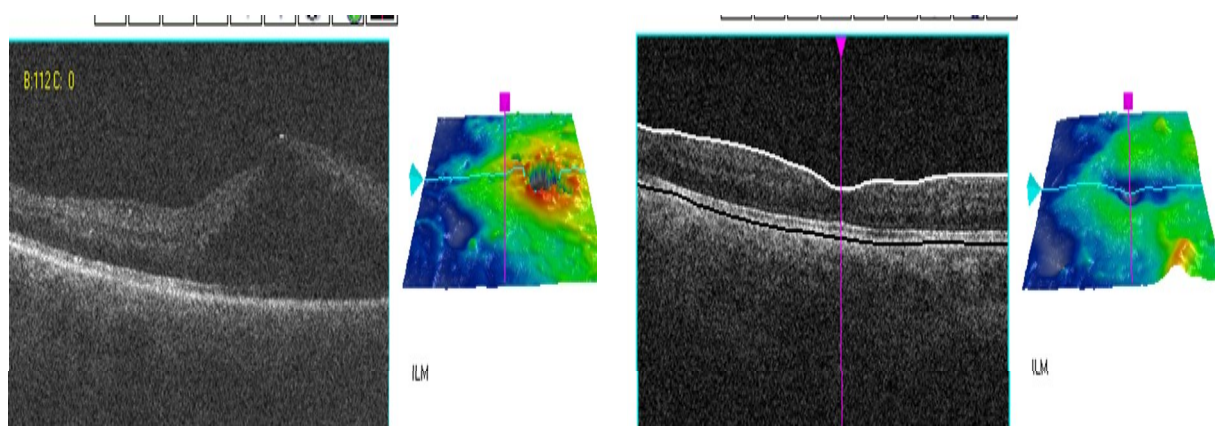
Hence my current philosophy is to use Laser first if appropriate (especially for those with circinates or defined leakage away from the centre of the vision) and then to consider anti-VEGF as a second line treatment. The exception are those with pure and extensive Foveal ie very central diabetic macular oedema. These are very often unresponsive to Macular grid laser.

As a result Lucentis is rarely available in the NHS, however some units are able to use Avastin (Bevacizumab) Thus world wide there is large experience of using Avastin (Bevacizumab) in diabetic macular oedema due to the cost effectiveness of the treatment.

Example of Patient with (DME)
3 Avastin injections given.
Vision improved from
COUNTING FINGERS to 6/12

Before

After



Treatment of diabetic retinopathy is entering an exciting new era, there remains much research and studies to fine tune treatment regimes but the outlook for diabetics has taken one major step forward.

Mr. Nicholas Lee 2011

Lead Ophthalmic Clinician at The Hillingdon Hospital

Consultant Ophthalmologist at The Western Eye Hospital

Mobile 07956 263804. Fax 01895 835404