

EXPLICIT CONTENT WARNING

THIS PRESENTATION CONTAINS GRAPHIC AND DISTURBING IMAGES INTENDED FOR MATURE AUDIENCES ONLY WHICH SOME VIEWERS MAY FIND DISTURBING. VIEWER DISCRETION IS ADVISED.

Jason Ho, ST5

23 October 2015

- 2.5 cases
- Referral Pathway
- Imaging and relevance to Dx

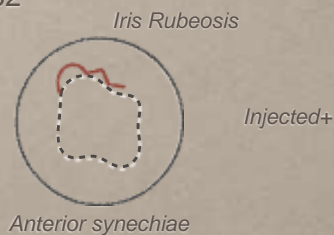
(1) NOT JUST ANOTHER NVG

- 42y F
- POHx: Loss of vision LE.
(Apr 2015) VA 6/9 “foggy vision” at WEH clinic
- PMHx: Cowden Syndrome, Rectal Ca → Br + Lung mets, surgery
- Semi-annual CT: (Jan 2015) “in remission”

6/9 VA PL

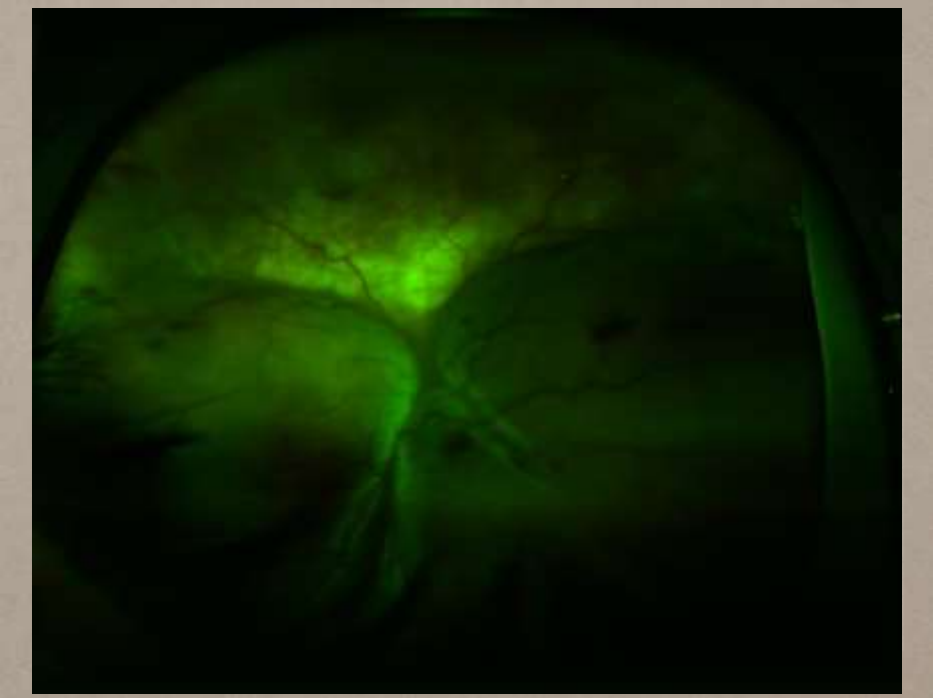
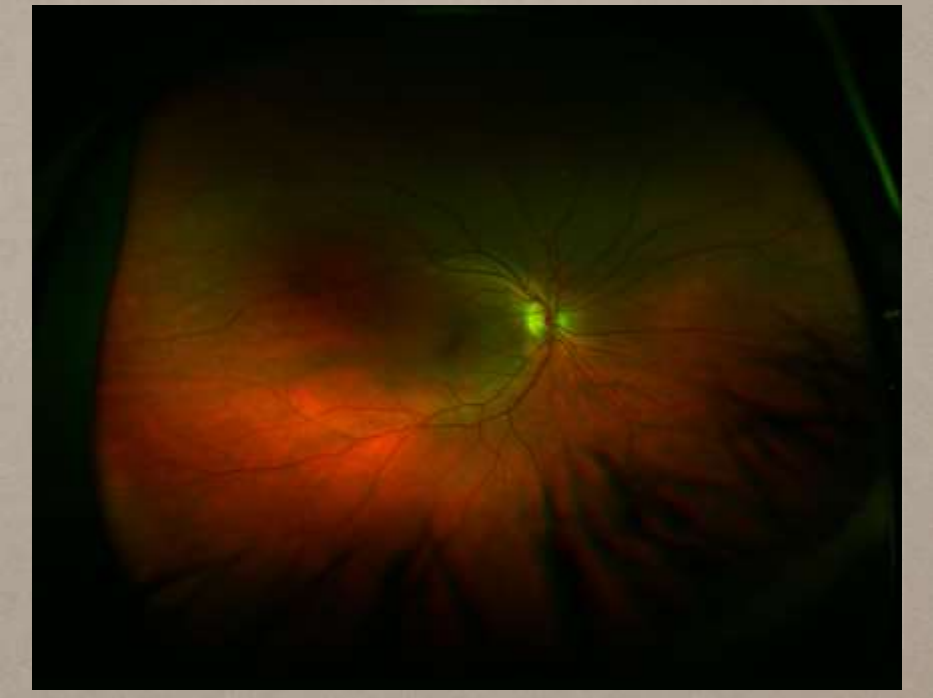
q AC cell++

14	32
----	----



D30r GONIO PAS 270-360, NVA

VITREOUS Hazy



- Subtotal exudative RD inferiorly
- Subretinal choroidal deposits superiorly
- RPE changes, haemorrhage
- B-scan + CT: extraocular intraconal orbital mass (17.9mm base, 9.7mm thick) close to optic nerve with some intraocular invasion (7.5mm base, 2.4mm thick)
- Repeat CT CAP: ?metastatic vs primary Ca (?hamartoma)

(2) CAN'T SEE, CELLULITIS R/V

- 83y M - seen with son
- POHx: "Cellulitis review" >3 weeks LE conjunctivitis
Rx oc Maxitrol, PO Augmentin
Son concerned re: worsening vision over the past year.
Glaucoma
Registered SSI
- PMHx: PMR, HTN, MGUS (UCH)
- SHx: lives alone, poor historian, ?Alzheimer's

CF VA HM

Mild chemosis, hyperaemia

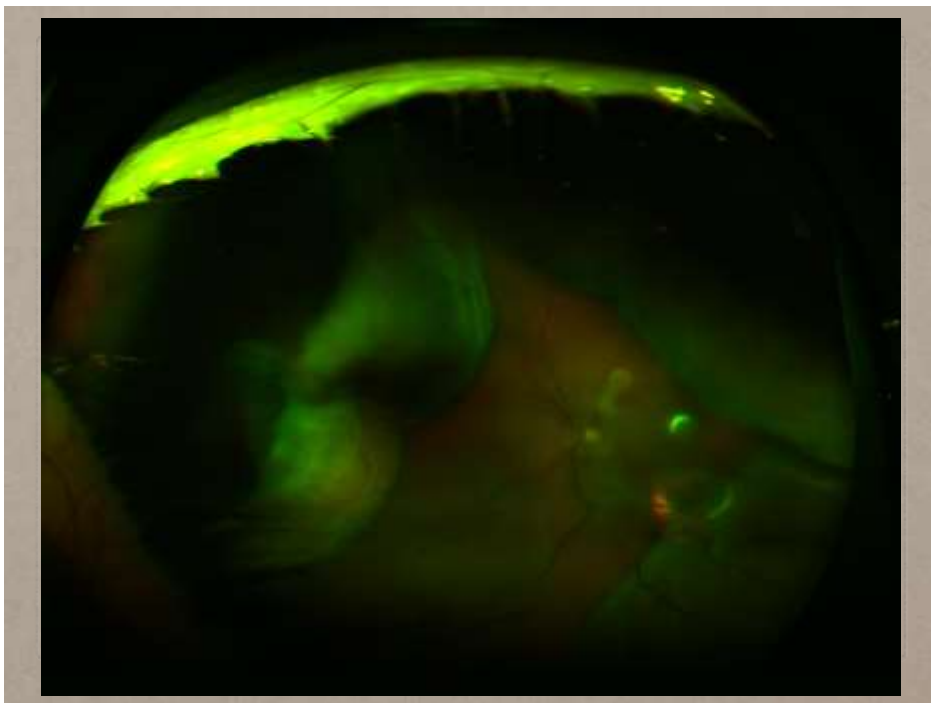
15	19
----	----

dq AC dq

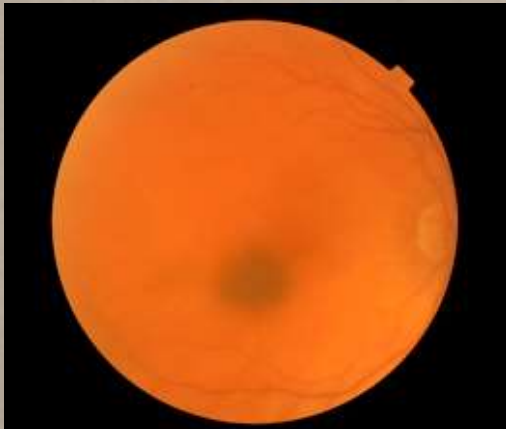IOL IOL

LE RAPD

EOM
full



- Bilobed pale mass nasally (14.5mm base, 5.7mm thick)
- Exudative RD
- Positive for internal blood flow
- ?Amelanotic melanoma vs ?metastatic deposit



Thickness > 2mm
Fluid (SRF)
Symptoms
Orange pigment
Margin near optic disc

0 features: <3% chance of growth at 5y
1 feature: 38%
2 or more features: >50%

EYE CANCER: REFER STAT

- Adult Ocular Oncology —> Moorfields/Barts via:
meh-tr.ocularoncology@nhs.net

- Retinoblastoma —> Royal London: Mr Mandeep Sagoo/Mr Ashwin Reddy via:

Tel: 020 3594 1419,

Fax: 020 3594 3262

SS-OCT

Wavelength-tunable laser - different light at frequencies tuned over a broad bandwidth with signal detected by photodetectors (not spectrometers)

Longer NIR-wavelength 1050nm

(cf 890nm SD-OCT)

1 micron resolution

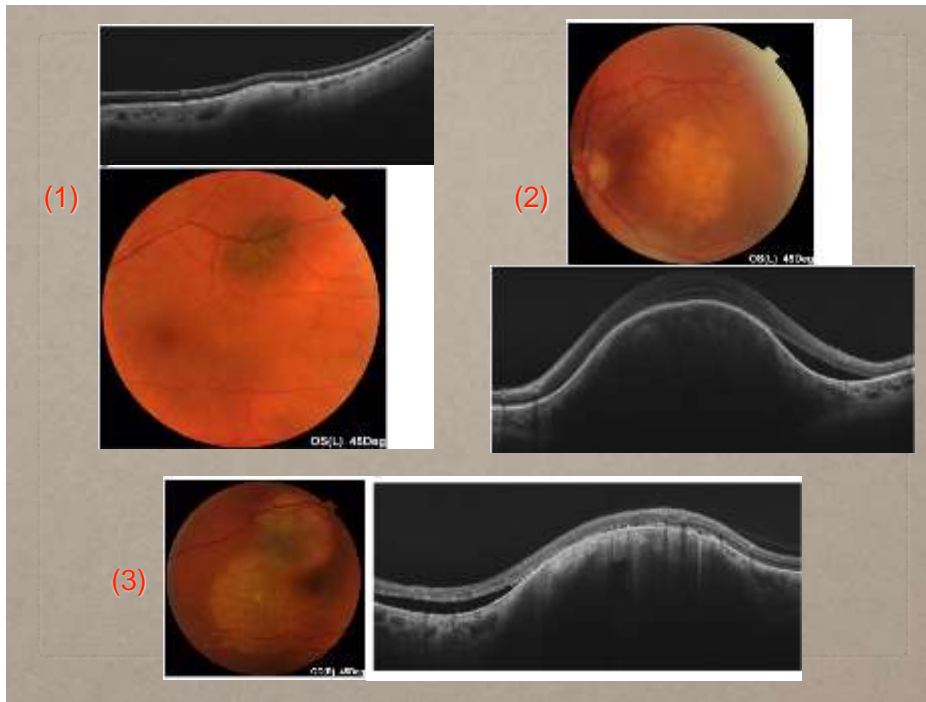
(5 micron SD-OCT)

100,000 A-scans per second

(cf 50,000 SD-OCT)

Less light scattering

Distinguish layers of choroid for better sub-RPE imaging



REFLECTION

- Old notes
- Empathy
- High index of suspicion
- OMG...what have I missed!?

